



WORLD JOURNAL OF CURRENT MEDICAL AND PHARMACEUTICAL RESEARCH

www.wjcmpr.com

ISSN: 2582-0222

Grade III bilateral trigger thumbs treated by prolotherapy: a case report

Alif Noeriyanto Rahman^{1,2}, Herry Herman^{2,3}, I Ketut Gede Arta Bujangga^{4*}, Jordan Sugiarto⁴

¹Fellow of International Pain Practice, Certified International Pain Sonologist, Educational Program Director of Comprehensive Course in Musculoskeletal Pain Intervention and Regeneration, Faculty of Medicine Universitas Padjadjaran, Orthopaedic and Pain Intervention Center of Sentra Medika Hospital, Depok, Indonesia

²Precursor - Comprehensive Course in Musculoskeletal Pain Intervention and Regeneration, Faculty of Medicine, Universitas Padjadjaran, Bandung, West Java, Indonesia

³Director of Comprehensive Course in Musculoskeletal Pain Intervention and Regeneration, Faculty of Medicine Universitas Padjadjaran, Department of Orthopaedic and Traumatology Hasan Sadikin General Hospital Faculty of Medicine Padjadjaran University, Bandung, West Java

⁴Department of Orthopaedic and Traumatology, Klungkung Regional General Hospital, Klungkung, Regency, Bali, Indonesia

Abstract

Introduction: Trigger Thumb is a condition that is caused by a thickened A-1 pulley, often secondary to a stenosed tendon sheath. There are several treatment options for trigger thumb, yet the use of prolotherapy to treat Trigger Thumb has not been widely discussed in the literature. Therefore, this study aims to present the case of Bilateral Trigger Thumbs which were treated using Prolotherapy.

Case: A 49-year-old female patient was admitted to the hospital with a complaint of inability to flex her both left & right thumbs two months ago. On physical examination, there was pain and swelling at the base, palmar side of her both thumbs, tender in consistency, and warm. There was a pain in daily activities using her both hands. There wasn't a history of trauma. The range of motion of both thumbs was decreased. The prolotherapy was given to the right thumb, yet the left thumb was treated by lidocaine injection only. After several treatments using prolotherapy, the right thumb showed better results compared to the left by increasing ROM, decreasing pain level and swelling, and the improving function of the right thumb.

Conclusion: In this case, the right thumb, which was treated with prolotherapy, has shown better results compared to the left thumb which was treated with medication only. We suggest prolotherapy to treat trigger fingers for the other patients in our hospital.

Article History:



Received: 04.10.2022
Revised: 19.10.2022
Accepted: 25.11.2022

Keywords:

Trigger thumb, Non-Operative, Prolotherapy.

*Corresponding Author

I Ketut Gede Arta Bujangga

E-Mail: dr_artabujangga@yahoo.com

DOI: <https://doi.org/10.37022/wjcmpr.v4i6.243>

This article is licensed under a Creative Commons Attribution-Non-commercial 4.0 International License.

Copyright © 2022 Author(s) retain the copyright of this article.



Introduction

Trigger finger/thumb (Stenosing Tenosynovitis) is a condition that is caused by a thickened A-1 pulley, often secondary to a stenosed tendon sheath [1]. Trigger finger is thought to be idiopathic, although there is a correlation with repetitive use of the affected hand as well as the history of diabetes, particularly type 1 diabetes [2]. The tendons become secondarily enlarged proximal to the tunnel, presumably because of repeated friction. The patient is unable to extend the involved finger actively. The finger can be extended passively and the extension occurs with a "snapping" motion. The patient is then able to flex the finger actively, but again with a "snapping" action similar to the action of a trigger. The nodular enlargement in the flexor tendons can be palpated just proximal to the base of the finger [3]. This study aims to present a case of Bilateral Trigger Thumbs treated by Prolotherapy.

Case Presentation

A 49-year-old female patient was admitted to the hospital with a complaint of pain at the base of her both left & right thumbs two months ago. Her daily job is at the salon, which was using her both hands actively. On physical examination, there was swelling at the base, palmar side of her both thumbs, tender in consistency, and warm. There was a pain in daily activities using her hands. The range of motion of both thumbs was decreased. She couldn't extend both of her thumbs actively.

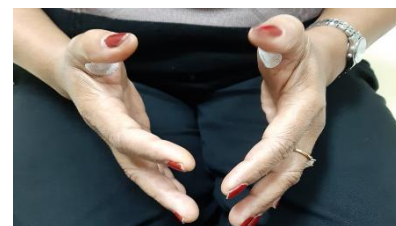
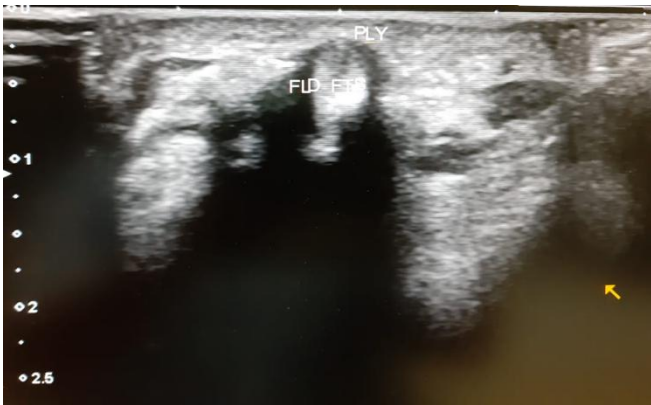


Figure 1. Bilateral Trigger Thumbs

The Ultrasonography showed direct visualization of the A1 pulley–flexor tendon complex, which was thickened.

Figure 2. Direct visualization of the A1 pulley–flexor tendon



complex

We treated the patient with oral medication and corticosteroid injections (Once) on both thumbs. From the first spuit (Equal to D12.5% in 10 cc spuit), we injected 1 cc of it into the right thumb. And from the second spuit (The mixed of Normal Saline + Lidocaine in 10 cc suit), we injected 1 cc of it to the left thumb. We did three injections in total, once every three weeks. The right thumb showed better results compared to the left by increasing ROM, decreasing pain level and swelling, improving the function of the right thumb, and loss of clicking. Whereas the pain level, stiffness, and clicking of the left thumb remain the same.

We did prolotherapy every three weeks, about three times. The ROM of the right thumb was great. The pain was highly decreased. The swelling was completely decreased.

Discussion

Trigger finger/thumb is one of the most common causes of hand pain in adults, affecting women six times more frequently than men. It is most common in patient's ages 40 to 60 years and often is found in the dominant hand, especially the fourth digit. The lifetime prevalence of trigger fingers is 2% to 3% in the general population, and up to 10% in patients with diabetes. In children, the condition is most common in those under the age of 8 years, affects boys and girls equally, and is more common in the thumb [2].

Figure 3. Green's Classification to Grade the Severity of

Grade I	Pain/history of catching
Grade II	Demonstrable catching, but can actively extend the digit
Grade III	Demonstrable locking, requiring passive extension
Grade IV	Fixed flexion contracture

Trigger Finger [4].

When patients flex a finger, the flexor tendon passes through a series of sheaths called annular and cruciform pulleys. These sheaths encapsulate the tendon, preventing it from separating from the bone when the finger is flexed, and letting the tendon glide smoothly back and forth during flexion and

extension. Trauma such as repetitive use or compression forces can cause tendon hypertrophy and sheath narrowing that prevents the tendon from sliding smoothly in the sheath and result in a catching or locking sensation. Because the greatest degree of force occurs at the first annular (A-1) sheath overlying the proximal interphalangeal joint, this sheath is the one most commonly affected in patients with trigger fingers. Chuang *et al* examined cadaver digits and found that when the finger flexes, the flexor tendon diameter increases as the tendon moves proximally through the sheaths. This would explain why tendon hypertrophy makes trigger fingers progressively difficult to extend [2].

The diagnosis of Trigger Finger is made clinically, and generally, no imaging is necessary [5]. The patient notices a click as the finger is flexed; when the hand is unclenched, the affected finger initially remains bent at the PIP joint but with the further effort it suddenly straightens with a snap. A tender nodule can be felt in front of the MCP joint and the click may be reproduced at this site by alternately flexing and extending the finger [6]. In recognition of Alphonse Henri Notta, the 19th-century French discoverer of this triggering condition, this tendon nodule is now commonly referred to as Notta's node [1]. Sonography allows direct visualization of the A1 pulley–flexor tendon complex [5].

The Differential Diagnosis includes Lumbrical Plus Finger, Joint Contracture, and Pyogenic Flexor Tenosynovitis. The paradoxical extensor phenomenon was first described and termed "lumbrical-plus" finger by Parkes, who described four conditions that cause it: (1) severance of FDP, (2) avulsion of FDP, (3) over-long flexor tendon graft, and (4) amputation through the middle phalanx. Severe adhesion between the FDP tendon and the lumbrical muscle is attributed to repeated trauma. There is an increased tension of lumbrical muscle which produces an imbalance between flexion and extension. Hence, in attempting flexion, the flexion force of the FDP transmitted through the tensed lumbrical to the lateral band, impaired the active flexion of the PIP joint. The release of the lumbrical muscle suffices for resolving this problem [7].

Digital stiffness is a common complication after trauma and surgery, and can markedly impair the function and quality of life of patients. Without treatment, this may result in permanent contractures. Although the practical demands of the hand vary between individuals, the basic functions of pinch, grasp, and grip are crucial for an independent productive life. Osseous stability with a congruent articular surface, integrity, and strength of the musculotendinous unit, tendon gliding, pliable skin and soft tissues are all required for a full digital range of motion (ROM) [8].

Pyogenic Flexor Tenosynovitis (PFT), also known as septic or suppurative flexor tenosynovitis, is a closed-space infection of the flexor tendon sheath of the hand. Pyogenic flexor tenosynovitis is a common problem and has been shown to make up 2.5% to 9.4% of all hand infections. Pyogenic flexor tenosynovitis can be caused by hematogeneous spread; however, local inoculation via lacerations, puncture wounds, and bites are more common causes. There is no standardized treatment algorithm for PFT in regards to the need for, timing, or type of surgical treatment. Many utilize a combination of

surgical decompression and sheath irrigation. However, despite prompt treatment, and regardless of the protocol used, complication rates can be high, leading to impaired function and even amputation of the affected digit [9].

Treatment

Treatments for trigger fingers range from conservative to invasive [2].

Noninvasive options Initial management of mild to moderate trigger finger symptoms may consist of a combination of nonsteroidal anti-inflammatory agents (NSAIDs), massage, heat, and/or ice. Splinting the digit in an extended position also can help rest the tendon and let the inflamed sheath heal. Exercises and passive stretches have been attempted in many patients but no research supports a clinically proven or widely accepted exercise model. Passive stretching and splinting are more commonly used in children to avoid surgical management [2].

Corticosteroid injections If conservative management fails, the first-line treatment is corticosteroid injections directly into the inflamed tendon sheath. For many patients, a single injection provides relief for up to 10 years. A second and occasionally third corticosteroid injection may be given 4 to 6 months apart, but typically the case is considered refractory and referred for surgical management after two to three unsuccessful treatment attempts. Adverse reactions to corticosteroid injections are rare but include fat necrosis or pigment changes at the injection site, infection, and tendon rupture [2].

Extracorporeal shock wave therapy (ESWT) A newer alternative to corticosteroid injections, ESWT is as effective in symptom management. This non-invasive therapy has been used for years for various other soft-tissue pathologies such as tennis elbow and plantar fasciitis but is just beginning to be studied in patients with trigger fingers. After transducer gel is applied to the patient's skin above the affected tendon, a probe is placed to deliver a shock wave. The mechanism of this therapy is not completely understood but ESWT may cause inflammation and stimulate the body's natural healing processes. ESWT is an option for patients who do not wish to undergo injections or surgery [2].

Surgery Surgical options include open surgical release and percutaneous release of the A-1 sheath. Open surgical release traditionally is used as first-line treatment in children, especially those with congenital trigger thumbs. Conservative management can be attempted in children but is historically unsuccessful. In adults, surgery is typically reserved for patients with a severe trigger finger that has failed conservative management. Although open surgical release has been practiced longer, no significant disparity in failure rate or several complications exists between it and percutaneous release. Risks of both types of surgery include nerve injury and incomplete release, and neither is widely accepted as superior at this time. Patients may prefer percutaneous release because it is less invasive; surgeons may prefer open surgery because of better visibility of the surgical field. Endoscopic release techniques, which improve visualization for surgeons and reduce scarring and healing time for patients, have been attempted. Endoscopy also reduces the risk of nerve or tendon

injury. However, this approach requires surgeons to master new techniques and facilities to obtain more sophisticated, costly instruments [2].

Prolotherapy it is an injection-based therapy for chronic musculoskeletal pain conditions. Originally termed "sclerotherapy" because of the early use of scar-forming sclerosants or procedures. Prolotherapy commonly consists of several injection sessions conducted every 2–6 weeks over the course of several months. Hypertonic dextrose is the most common injectant. The most common prolotherapy agent used in clinical practice is dextrose, with concentrations ranging from 12.5% to 25% [14]. During an individual prolotherapy session, a dextrose solution is injected at sites of tender ligaments, tendon attachments, and adjacent joint spaces. Injected solutions are hypothesized to cause local irritation, with subsequent inflammation and anabolic tissue healing, improving joint stability, biomechanics, function, and ultimately, decreasing pain. Animal model studies suggest an injectant-specific biological effect and have focused on inflammation and ligamentous size and strength. Dextrose has been reported to produce a local inflammatory response in a rat knee ligament model. Injured medial collateral rat ligaments that were injected with dextrose had a significantly larger cross-sectional area than both noninjured and injured saline-injected controls [11]. Hauser *et al* concluded that the use of dextrose prolotherapy was supported for the treatment of tendinopathies, knee and finger joint OA and spinal/pelvic pain due to ligament dysfunction [13].

The most common complications of trigger thumb involve persistent pain, swelling, or stiffness. Other complications include persistent or recurrent triggering, contracture, superficial infection, deep infection, neurapraxia, and bowstringing [10].

Conclusion

Trigger thumb is one of the most common diagnoses of hand pain in adults. Nearly all patients complain of some level of discomfort and locking of a digit that is worse in the morning or after repetitive use of their hands throughout the day. Studies suggest that the best and most cost-effective treatment is immediate surgical release in the clinic (for patients with diabetes) and one to two corticosteroid injections, followed by definitive surgery, if needed (for patients without diabetes). In this case, the right thumb, which was treated with prolotherapy, has shown a better result compared to the left thumb which was treated with oral medication and corticosteroid injection only. We suggest prolotherapy to treat trigger fingers for the other patients in our hospital. A further follow-up with the patient is important to ensure the effectiveness of prolotherapy.

References

1. Clapham PJ, Chung KC. A Historical Perspective of the Notta's Node in Trigger Fingers. *J Hand Surg Am*. 2009;34(8):1518–22. Available from: <https://doi.org/10.1016/j.jhsa.2009.04.041>
2. Matthews A, Smith K, Read L, Nicholas J, Schmidt E. Trigger finger: An overview of the treatment options. *J Am Acad Physician Assist*. 2019;32(1):17–21. Available from:

<https://doi.org/10.1097/01.JAA.0000550281.42592.97>

3. Salter RB. 1999. Textbook of Disorders and Injuries of the Musculoskeletal System. Section II: Musculoskeletal Disorders-General and Specific. Third Edition. USA: Lippincott Williams & Wilkins. Pg 158-59.
4. Dala-Ali BM, Nakhdjevani A, Lloyd MA, Schreuder FB. The efficacy of steroid injection in the treatment of trigger finger. Clin Orthop Surg. 2012;4(4):263-8. Available from: <https://doi.org/10.4055/cios.2012.4.4.263>
5. Soldati G, Iacconi P. Sonographic appearance of ARDS: Letter: Ref. Tsubo T, Yatsu Y, Suzuki A, Iwakawa T, Okawa H, Ishihara H, Matsuki A (2001) Daily changes of the area of density in the dependent lung region - Evaluation using transesophageal echocardiography. Intensive Care Med 27:1881-1886 [5]. Intensive Care Med. 2002;28(11):1675. Available from: <https://doi.org/10.1007/s00134-002-1484-2>
6. Abe Y, Tominaga Y. Paradoxical extension phenomenon of the little finger due to repetitive trauma to the palm. Hand Surg. 2012;17(2):255-7. Available from: <https://doi.org/10.1142/S0218810412720288>
7. Catalano LW, Alton Barron O, Glickel SZ, Minhas S V. Etiology, evaluation, and management options for the stiff digit. J Am Acad Orthop Surg. 2019;27(15): E676-84. Available from: <https://doi.org/10.5435/JAAOS-D-18-00310>
8. Solomon, L., Warwick, D., Nayagam, S., & Apley, A. G. (2017). *Apley's system of orthopedics and fractures* (10th ed.). London: Hodder Arnold. Pg 439-40.
9. Chapman T, Ilyas AM. Pyogenic Flexor Tenosynovitis: Evaluation and Treatment Strategies. J Hand Surg Am [Internet]. 2019;44(11):981-5. Available from: <https://doi.org/10.1016/j.jhsa.2019.04.011>.
10. Everding NG, Bishop GB, Belyea CM, Soong MC. Risk factors for complications of open trigger finger release. Hand. 2015;10(2):297-300. Available from: <https://doi.org/10.1007/s11552-014-9716-9>
11. Rabago D, Nourani B, Weber MJ. Prolotherapy for Chronic Musculoskeletal Pain [Internet]. Fourth Edition. Integrative Medicine: Fourth Edition. Elsevier Inc.; 2018. 1047-1053.e2 p. Available from: <http://dx.doi.org/10.1016/B978-0-323-35868-2.00112-2>.
12. Doyle JR. Palmar and digital flexor tendon pulleys. Clin Orthop Relat Res. 2001;383(383):84-96. Available from: <https://doi.org/10.1097/00003086-200102000-00011>
13. Hauser RA, Lackner JB, Steilen-Matias D, Harris DK. A systematic review of dextrose prolotherapy for chronic musculoskeletal pain. Clin Med Insights Arthritis Musculoskelet Disord. 2016;9:139-59. Available from: <https://doi.org/10.4137/cmamd.s39160>
14. Moshirif A, Elwan M. The effect of addition of buffered dextrose 5% solution on pain occurring during local steroid injection for the treatment of plantar fasciitis: A randomized controlled trial. Muscles Ligaments Tendons J. 2019;9(4):525-30. Available from: <https://doi.org/10.32098/mltj.04.2019.06>